



**PATIENT**  
Kiwi Mackintosh

**PRESENTING CLINICAL SIGNS**

History: Progressive heart murmur, now grade III-IV/VI. No clinical signs. BP: 132, 135, 136, 138mmHg.

**SPECIES**  
Feline

**ECHOCARDIOGRAM FINDINGS**

2D, m-mode, color flow and Doppler imaging is available.

**Left ventricle:** The LV diameter is normal with adequate myocardial function. The LV wall thicknesses are mildly increased symmetrically. There is a mildly hyperechoic endocardium consistent with fibrosis. The papillary muscles are mildly hypertrophied and hyperechoic. The endocardium appears mildly remodeled.

**BREED**  
Maine Coon Mix

**Left atrium:** The left atrium is normal. No smoke or thrombi seen.

**SEX**  
Female Spayed

**Mitral valve:** The MV leaflets appears normal. Systolic anterior motion is seen on 2D and color flow imaging. Mild eccentric MR.

**AGE**  
7 years

**Aortic valve/Aorta:** The aortic valve is normal in morphology and mobility. Significantly elevated aortic outflow velocity with a dynamic profile. No aortic insufficiency.

**Right ventricle:** Normal right ventricular diameter and morphology indicating no overt evidence of pulmonary arterial hypertension.

**Right atrium:** The right atrium is normal in dimension.

**WEIGHT**  
10lbs

**Tricuspid valve:** The tricuspid valve appears normal with trace tricuspid regurgitation.

**Pulmonary valve/Pulmonary artery:** The pulmonic valve is normal in morphology and mobility. No pulmonic insufficiency. Normal RVOT velocity; laminar flow.

**Pericardium/other:** No pericardial or pleural effusion noted. No obvious cardiac masses.

**INTERPRETED BY**

Maggie Machen  
Lamy, DVM  
DACVIM (Cardiology)

**2-Dimensional Measurements**

Ao diam (cm)	1.0
LA diam (cm)	1.2
LA:Ao (Swe)	1.2
IVS thickness (cm)	0.61
LVID diastole (cm)	1.36
PW thickness (cm)	0.61
LVID systole (cm)	0.5
FS (%)	66

**Doppler Measurements**

PV Vmax (m/s)	0.92
AoV Vmax (m/s)	5.5
MR Vmax (m/s)	NA
TR Vmax (m/s)	NA
TR PG (mmHg)	NA

**IMAGING PERFORMED BY**

Pamela Harrigan,  
RDCS

**INTERPRETATION OF THE FINDINGS**

The diagnosis and cause of the murmur is hypertrophic obstructive cardiomyopathy. This indicates some degree of LV thickening (mild in this case) with a dynamic LVOT obstruction (SAM). The degree of disease appears mild with mild LVH and no left atrial enlargement, indicating the risk for spontaneous CHF and/or a thrombotic event is currently low. No additional issues are identified.

**HOSPITAL NAME**

VCA Palmer

**REFERRING VET**

Dr. Haroules

While no medications have been shown to definitively alter long term outcome at this stage of disease, atenolol is often initiated to decrease the outflow obstruction. If the patient is easily medicated, this would be reasonable. An alternative approach would be to simply monitor for the next 6 months. Discussion with the owner is advised.

**INVOICE**  
29112

Prognosis is guarded given the highly variable nature of feline cardiomyopathy.

**DATE**  
2/20/23



**PATIENT**

Kiwi Mackintosh

**SPECIES**

Feline

**BREED**

Maine Coon Mix

**SEX**

Female Spayed

**AGE**

7 years

**WEIGHT**

10lbs

**INTERPRETED BY**

Maggie Machen  
 Lamy, DVM  
 DACVIM (Cardiology)

**IMAGING PERFORMED BY**

Pamela Harrigan,  
 RDCE

**HOSPITAL NAME**

VCA Palmer

**REFERRING VET**

Dr. Haroules

**INVOICE**

29112

**DATE**

2/20/23

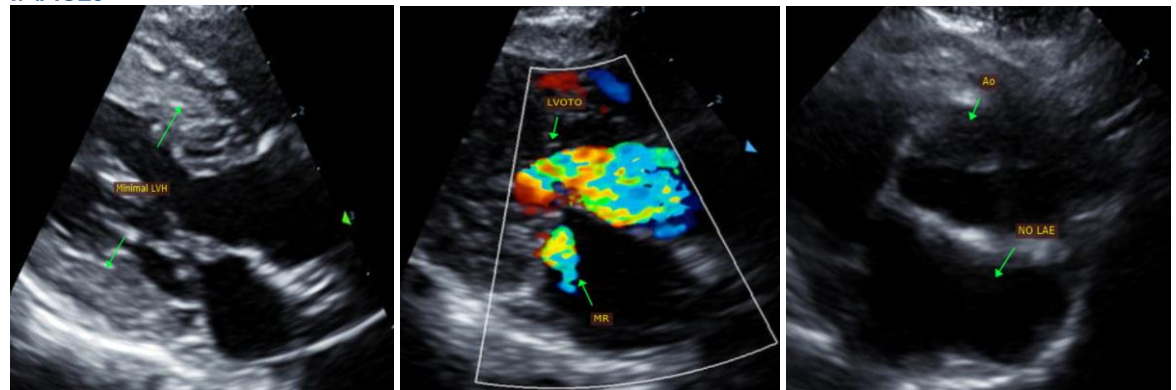
**RECOMMENDATIONS**

- If elected, institute Atenolol 25mg tablets; Give ¼ tab once daily. Recheck heart rate in 1-2 weeks with target stressed rate of 140-160bpm 12-24 hours post-administration. Increase as needed until target reached.
- Anesthetic risk is considered mild, however judicious IV fluid rates are advised to avoid fluid overload. Additionally, drugs that stimulate heart rate should be avoided unless clinically necessary (glycopyrrolate, atropine). Avoid vasodilators as this may worsen the obstruction. A reasonable protocol includes opioid/benzodiazepine premedication, propofol induction, isoflurane maintenance. Additionally, steroids should be used with caution on older cats, as even a 'normal' geriatric heart can develop evidence of intolerance and fluid retention.
- Monitor for any clinical evidence of cardiac compromise, including respiratory changes and/or signs of a blood clot event (paralysis, neurologic changes, etc.).

**PLAN**

- Baseline BP and T4 are recommended every 6 months.
- Recommend recheck echocardiogram in 6 months to assess rate of progression, sooner if any issues arise in the interim.

**IMAGES**



The information and recommendations provided are based on the images presented by the referring veterinarian. No evaluation can be communicated regarding pathology that was not visible in the image/video clips provided.

Thank you for this referral. This report was generated using transcription software, and minor dictation errors may be present. If the clinical or image interpretation does not parallel your findings or if I can be of any further assistance, please contact me.

**Maggie Machen Lamy, DVM**  
 Diplomate of the American College of Veterinary Internal Medicine (Cardiology)  
 info@sonopath.com

**Echocardiogram performed by:** Pamela Harrigan, RDCE  
 Pet Animal Ultrasound Service ([4paus.com](http://4paus.com))